
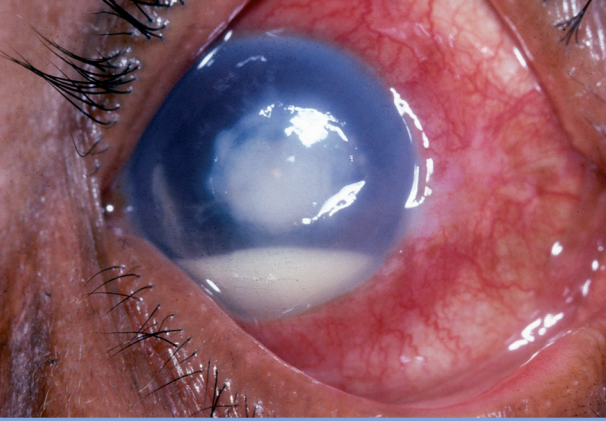
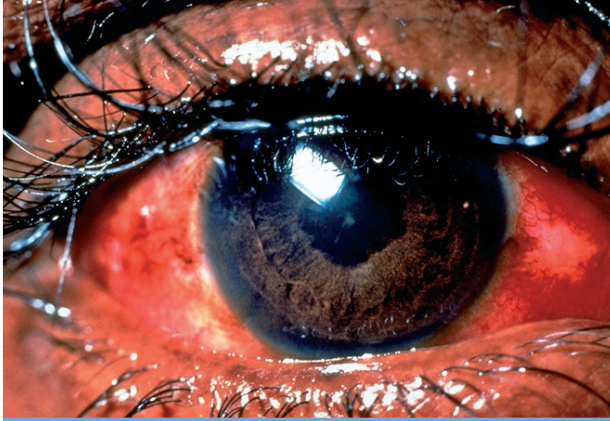
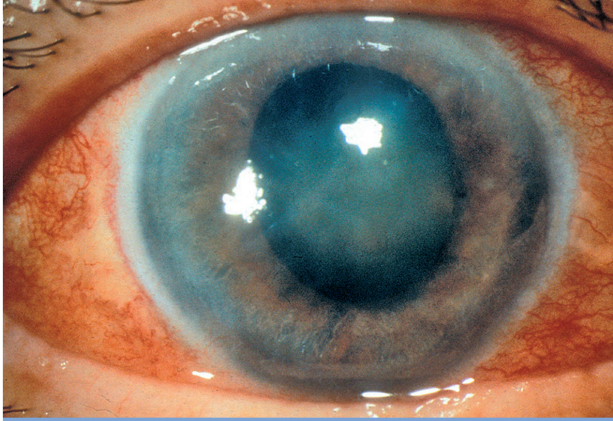


Primary Level Management RED EYE NO INJURY

Differential diagnosis of red eye with no injury

				
	Conjunctivitis	Corneal ulcer	Acute iritis	Acute glaucoma
Eye	Usually both eyes	Usually one eye	Usually one eye	Usually one eye
Vision	Normal	Usually decreased	Often decreased	Marked decrease
Eye pain	Normal or gritty	Usually very painful	Moderate pain, light sensitive	Severe pain (headache and nausea)
Discharge	Sticky	Watery	Watery	Watery
Conjunctiva	Generalised (variable) redness	Redness most marked around the cornea	Redness most marked around the cornea	Generalised redness
Cornea	Normal	Grey, white spot (fluorescein staining)	Usually clear, (keratitic precipitates may be visible with magnification)	Hazy (due to fluid in the cornea)
Anterior chamber (AC)	Normal	Occasionally creamy fluid level in the anterior chamber (hypopyon)	Cells will be visible with magnification	Shallow or flat
Pupil size	Normal and round	Normal and round	Small and can be irregular	Mid-dilated and oval
Pupil response to light	Active	Active	Minimal reaction as already small	Minimal or no reaction
Intraocular pressure (IOP)	Normal (but do not attempt to measure IOP). NB Risk of infection	Normal (but do not attempt to measure IOP)	Normal or slightly raised	Raised
Photophobia	Slight	Significant	Significant	None
Useful diagnostic sign / test	Discharge in both eyes with clear cornea, normal pupil and normal vision	White spot or mark on the cornea which stains with fluorescein	Small pupil which becomes irregular as it dilates	Very painful eye with poor vision and dilated pupil. Raised IOP and shallow AC

Management of a red eye with no injury

Conjunctivitis	Corneal ulcer	Acute iritis	Acute glaucoma
Treat	Refer	Refer	Refer
Antibiotic ointment x 3/day for 5 days. Advise on hygiene	Hourly antibiotic drops or ointment	Dilate the pupil only if diagnosis is confirmed	Oral diamox 500 mg and pilocarpine drops only if diagnosis is confirmed